Infarction -> An area of ischaemic necrosis w/in a tissue or organ prod. by either it's arterial supply or it's venous drainage. Usually result from arterial occlusion -> ① Thrombosis in CA -> myocardial infarct ② Embolism e.g. lung, kidney, spleen ③ Thrombosis or Embolism e.g. brain (but also hypotension)

3 main epicardial arteries are effectively end arteries so if occluded -> no bf.
- left ant. desc CA -> Supplies Ant $\frac{2}{3}$ of Septum + ant wall.
- right CA -> Supplies post $\frac{1}{3}$ of Septum + post wall of heart
- circumflex CA -> Supplies left lat. wall.

• MI is pale white because of ↑. Pulm embolism is more dark/red as other bv grow + try to perfuse the area.

Embolism -> Transfer of abnormal material by the blood stream and it's impaction in a vessel. (Tle embolus)

Types -> Fragments of thrombus (most common), atheramatous plaques, septic emboli, fragment of tumour, fat, air, parenchymal cells.

Thrombi ->

White/Pale -> Form in fast flowing blood. consist almost entirely of platelets.

Red/haemorrhagic -> Form in slow/stagnant blood so there is enough time for coagulation cascade to make a mesh of fibrin which traps RBC w/in it.

Venous Infarction -> Much less common. It is unlikely to get venous occlussion as most tissues have venous anastomoses. Can occur in intestines (thrombosis of mesenteric veins). Also in brain in Sup. Sag. Sinus (longitudinal) and in testes/ovary from torsion/twisting.

Heart Infarction -> Acute Myocardial Infarction is leading COD in UK.

Regional/ ① Transmural -> ischaemic necrosis involves full/nearly full thickness of vent. wall in the distribution of a single coronary artery. Usually associated w/ coronary atherosclerosis, plaque rupture, superimposed thrombosis. (STEMI)

② Subendocardial -> ischaemic necrosis involving inner $\frac{1}{3}$-$\frac{1}{2}$ of vent. wall. Diffuse stenosing of coronary atherosclerosis and global ↓ in coronary flow. (e.g. due to shock) but NO plaque rupture or thrombosis. (NSTEMI)

Myocardial cells w/out nuclei = MI. If nuclei still present

DVT and Pulmonary Emboli -> PE results from detachment of thrombus in a systemic vein, commonly in leg (Deep vein Thrombosis). PE is most common at day 10 post-op. Death is immediate or after a short period of resp distress.

• If pt lives, damage dep. on amount blocked.

* Pulm HT causes pulm atherosclerosis *

Types of Infarction ->

Red/haemorrhagic

White/pale/anaemic -> occur w/ ① arterial occlusion ② in solid tissues e.g. heart, spleen, kidney

Septic infarts - bacterial contamination

Blood infarts - no ↑

Complications ->

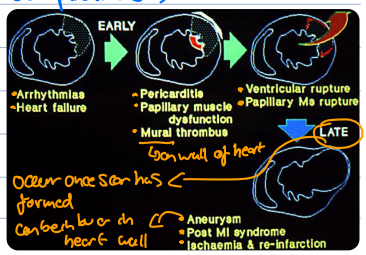

Morphological Complications Following MI ->

① Cardiac Rupture -> (1-5%) mechanical weakening in necrotic + inflamed myocardium. @ 4-7d

② Pericarditis -> @ 2-3d Fibrous + localized to region over necrotic area.

③ Mural Thrombosis -> (15-40%) Combination of myocardial abnormality in contractility (causing stasis) and endocardial damage (causing thrombogenic surface).

④ Ventricular Aneurysm -> Scar tissue that bulges during systole.

Infarction and Embolism

Epicardial end arteries
- left ant. desc. CA -> ant. $\frac{2}{3}$ Septum + ant. wall
- right CA -> post $\frac{1}{3}$ Septum + post. wall
- circumflex CA -> left lat. wall

RCA (post.)
LADA (ant.)
Circumflex A (lat.)

AMI (acute MI) -> leading COD in UK.
- Transmural: ischaemia in full thickness of wall] STEMI
- Subendocardial: ischaemia in inner $\frac{1}{3}$-$\frac{1}{2}$ of vent. wall.] NSTEMI

MI is pale, PE is darker as bv grow to try + perfuse the area.

Post-MI complications -> ① Cardiac rupture (weakened walls) @ 4-7d
② Pericarditis @ 2-3d
③ Mural thrombosis - abnormal contractility + endocardial damage.
④ Ventricular aneurysm - scar tissue bulging

Embolism -> Transfer of abnormal material by bloodstream.
↳ Types: Thrombus fragments, atheramatous plaques, septic emboli, tumour, fat, air.

Thrombus
- anaemic: white - mostly platelets - forms in fast flowing blood (arterial occlusion)
- haemorragic: red - mesh of fibrin + trapped RBC - forms in slow/stagnant blood.